

A patient with huge hepatocellular carcinoma who had a complete clinical response to p53 gene combined with chemotherapy and transcatheter arterial chemoembolization

Geng Tian, Jiliang Liu and Jie Sui

The prognosis of hepatocellular carcinoma (HCC) is poor and current therapies are largely ineffective. Transcatheter arterial chemoembolization is a standard treatment option for patients with unresectable HCC, especially when combined with other therapies. We report a 62-year-old male with huge HCC. The patient was first treated with adenovirus-mediated wild-type p53 gene (Ad-p53, gendicine) combined with oxaliplatin (200 mg) and transcatheter arterial chemoembolization or transcatheter arterial chemotherapy for two cycles. Review showed tumor shrinkage and a decrease in α -fetoprotein. Oxaliplatin was stopped because of side effects. Then the patient was treated with a tumor feeding arterial injection of Ad-p53 (1×10^{12} viral particles) twice and Ad-p53 (1×10^{12} viral particles) followed by 5-fluorouracil (500–750 mg) six times through port-catheter system. We observed marked tumor shrinkage and sustained normal

α -fetoprotein and liver function during a 614-day follow-up period. *Anti-Cancer Drugs* 20:403–407 © 2009 Wolters Kluwer Health | Lippincott Williams & Wilkins.

Anti-Cancer Drugs 2009, 20:403–407

Keywords: chemotherapy, gene therapy, hepatocellular carcinoma, p53 gene, transcatheter arterial chemoembolization

Department of Tumor, Shenzhen Second People's Hospital, South Medical University, Shenzhen, China

Correspondence to Associate Professor Geng Tian, Department of Tumor, Shenzhen Second People's Hospital, South Medical University, 3002 Sungang West Road, Shenzhen 518035, China
Tel: +86 137 2439 5569; fax: +86 755 8335 6952;
e-mail: gengtian71@yahoo.com.cn

Received 9 October 2008 Revised form accepted 25 November 2008

Introduction

Worldwide, hepatocellular carcinoma (HCC) is one of the five most common cancers and the third most common cause of cancer-related death [1]. The prognosis of HCC is poor and current therapies are largely ineffective. Transcatheter arterial chemoembolization (TACE) has become the standard treatment for unresectable HCC [2]. However, this method is often unsuccessful. Genetic abnormalities are commonly seen in HCC tumors particularly with inactivation of the p53 tumor suppressor. Inactivity of p53 results in an impaired cellular response to various stresses, including DNA damage, growth factor withdrawal, and oncogenic transformation, as well as to genomic instability [3]. Extensive basic research on the p53 gene facilitated its clinical application. In this study, we report a 62-year-old man with a huge HCC who was treated with Ad-p53 (gendicine, Shenzhen Sibiono Gentech, Shenzhen, China) combined with chemotherapy and TACE, which resulted in a good clinical prognosis.

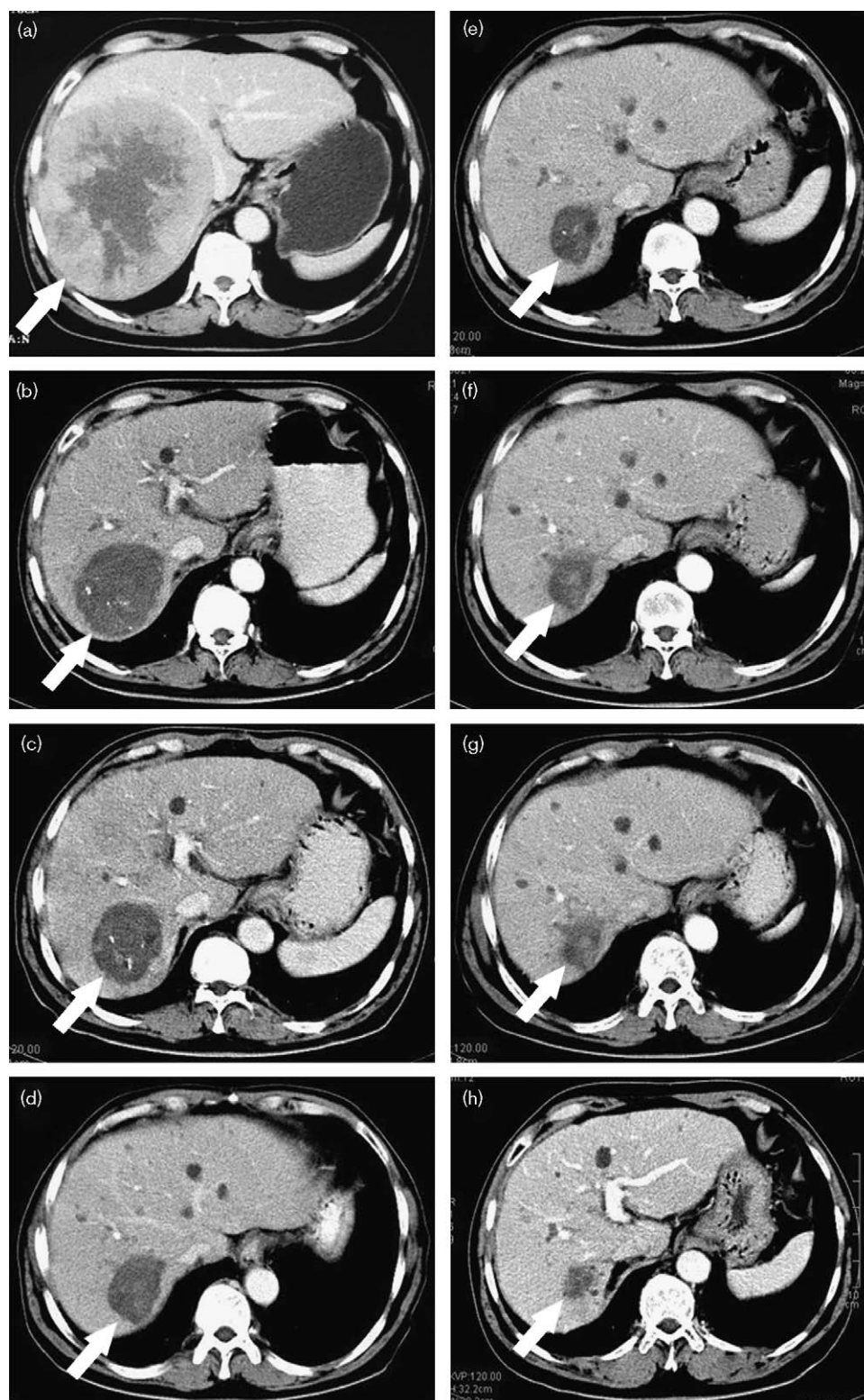
Case description

A 62-year-old man was admitted to our hospital because of a huge hepatic mass that had been identified on computed tomography (CT). The patient suffered from chronic hepatitis B and liver cirrhosis. Three days before admission, the patient received abdominal dynamic enhanced CT in another hospital because of 3-month

abdominal distention and anorexia and 2-week right upper quadrant pain. The CT showed that a 16×13.5 cm tumor was present in the right hepatic lobe in the arterial phase, suggesting HCC (Fig. 1a). Laboratory data on admission were as follows: red blood cells $4.78 \times 10^{12}/l$; hemoglobin 14.4 g/l; white blood cells, $6.35 \times 10^9/l$; platelet count $170.4 \times 10^9/l$; total bilirubin 16.0 $\mu g/l$; alanine transaminase 76 IU/l; glutamic-oxalacetic transaminase 56 IU/l; γ -glutamyl transpeptidase 52 IU/l; total protein 78 g/l; albumin 37.5 g/l; no ascites; and no hepatic encephalopathy. Hepatic function was classified as Child A. α -Fetoprotein (AFP) was 12947.3 $\mu g/l$ (normal value, < 8.1). Hepatitis B virus antigen was positive, whereas anti-hepatitis C virus antibody was negative.

On the basis of the above findings, HCC was diagnosed. The lesion occupied more than 50% of the liver volume, which precluded operation. We decided to treat this patient with a combination therapy of TACE, chemotherapy, and Ad-p53 based on the following considerations. First, TACE is a standard local treatment option for patients with unresectable HCC, especially when combined with other therapies. Second, oxaliplatin plus 5-fluorouracil (5-FU) or capecitabine shows promising antitumor activity in patients with advanced HCC, especially in Chinese patients (most patients with underlying chronic hepatitis B) [4,5]. Third, Ad-p53 (gendicine) is approved as a new class of drug for cancer treatment and extensive

Fig. 1



Abdominal computed tomography (CT) images. An abdominal dynamic enhanced CT obtained 6 days before treatment (a) shows a right hepatic lobe hypervascular huge mass, 16 by 13.5 cm (arrow). A CT scan obtained 119 days after start of treatment (b) showed that the lesion became an 8 × 6 cm hypovascular lesion. Lipiodol retention within the lesion can be seen. A CT scan obtained 161 days after start of treatment (c) showed that the size of the lesion was 6 × 5 cm (arrow). Lipiodol retention within the lesion can be seen. A CT scan obtained 282 days after start of treatment (d) showed that the size of the lesion was 5 × 3.5 cm (arrow). A CT scan obtained 363 days after start of treatment (e) showed that the size of the lesion was 4.5 × 3.5 cm (arrow). Lipiodol retention within the lesion can be seen. A CT scan obtained 456 days after start of treatment (f) showed that the size of the lesion was 4 × 3.5 cm (arrow). A CT scan obtained 553 days after start of treatment (g) showed that the size of the lesion was 4 × 3 cm (arrow). A CT scan obtained 828 days after start of treatment (h) showed that the size of the lesion was 3 × 2 cm (arrow).

basic research on the p53 gene facilitated its clinical application [6,7].

The patient gave his written informed consent for the therapy, which was approved by the Scientific and Ethics

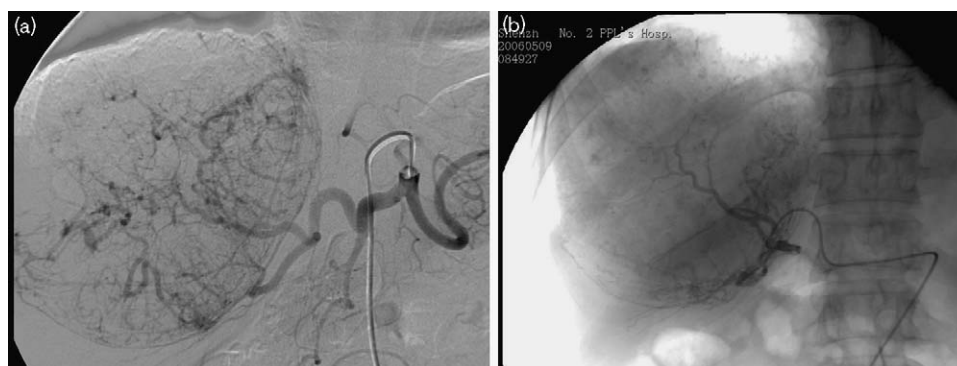Table 1 Treatments and changes of α -fetoprotein

Time from start of treatment (day)	Treatment ^a	α -Fetoprotein (μ g/l)
0	Transcatheter arterial chemoembolization, recombinant adenovirus p53	12947.3
2	Oxaliplatin	
6		13322.3
16	Transcatheter arterial chemotherapy, recombinant adenovirus p53	6260.5
26	Oxaliplatin	
28	Recombinant adenovirus p53	
34		5170.2
35	Recombinant adenovirus p53	
118		236.9
125	Recombinant adenovirus p53 + 5-fluorouracil	
131	Recombinant adenovirus p53 + 5-fluorouracil	
153		28.6
155	Recombinant adenovirus p53 + 5-fluorouracil	
162	Recombinant adenovirus p53 + 5-fluorouracil	
205		19.8
208	Recombinant adenovirus p53 + 5-fluorouracil	
214	Recombinant adenovirus p53 + 5-fluorouracil	
279		4.8
358		2.7
455		3.3
638		1.3
828		4.2

^aOxaliplatin given by intravenous infusion. Recombinant adenovirus p53 and 5-fluorouracil given by hepatocellular carcinoma feeding artery injection through a port-catheter system.

Committee of Shenzhen Second People's Hospital of South Medical University. The patient received Ad-p53 plus TACE on 19 April 2006 (Table 1). Diagnostic hepatic angiography confirmed tumor blush (Fig. 2a). After injection of Ad-p53 [1×10^{12} viral particles (VPs)] into the tumor-feeding artery through a catheter, an emulsion of lipiodol (10 ml), tetrahydropyranyl adriamycin (60 mg), and 5-FU (1000 mg) was used for chemoembolization. Oxaliplatin (200 mg) was given by intravenous infusion 2 days later. On day 20 after TACE, the patient received Ad-p53 plus transcatheter arterial chemotherapy (TAC); hepatic arteriography showed that the tumor had decreased to 14×11.5 cm and the artery vascularity of the mass had decreased (Fig. 2b). After injection of Ad-p53 (1×10^{12} VPs) into the tumor-feeding artery through a catheter, 5-FU (750 mg) and tetrahydropyranyl adriamycin (50 mg) were used for TAC. A port-catheter system (PCS) with its tip placed in the tumor-feeding artery was implanted after TAC. Another course of oxaliplatin (200 mg) was given by intravenous infusion 26 days after TACE. Review showed that AFP decreased and a B-mode ultrasound examination showed tumor shrinkage. On account of nausea (National Cancer Institute's Common Toxicity Criteria: grade 3) and vomiting (grade 2), which were caused by oxaliplatin, the patient refused to continue the use of oxaliplatin. Before the patient recovered from the side effects of chemotherapy, we only used Ad-p53 (1×10^{12} VPs) during the first two times of tumor-feeding artery injection through PCS. Then the patient was treated with the injection of Ad-p53 (1×10^{12} VPs) followed by 5-FU (500–750 mg) six times through PCS (Table 1). Drugs were injected into the hepatic artery through PCS within 2 min every time. PCS was filled with heparinized saline (1×10^5 IU/l) after each injection. The tumor had reduced to 6×5 cm and its vascularity decreased significantly 5

Fig. 2



Hepatic digital subtraction angiography images. A digital subtraction angiography image (a), obtained after the administration of contrast material, shows heterogeneous arterial enhancement and a hepatic mass, 16×13.5 cm (arrow). Twenty days after the patient had undergone a tumor feeding artery injection of recombinant adenovirus p53 combined with transcatheter arterial chemoembolization and 18 days after intravenous infusion of oxaliplatin, a digital subtraction angiography image (b) showed that the mass decreased to 14×11.5 cm (arrow) and the artery vascularity of the mass decreased. The tip of the catheter was placed in the tumor-feeding artery.

months after starting treatment (Fig. 1c), and the patient had normal liver function and was in good clinical health with AFP decreased to 28.6 µg/l (Table 1). After the last tumor-feeding artery injection of Ad-p53 and 5-FU on post-TACE day 214, the patient underwent follow-up but received no more therapy for HCC. The patient was reviewed on post-TACE day 828 (614 days after finishing treatment) and the data were as follows: red blood cells $4.63 \times 10^{12}/l$; hemoglobin 14.9 g/l; white blood cells $4.2 \times 10^9/l$; platelets $89 \times 10^9/l$; total bilirubin 13.9 µmol/l; alanine transaminase 48 IU/l; glutamic-oxalacetic transaminase 41 IU/l; γ-glutamyl transpeptidase 26 IU/l; total protein 83.7 g/l; albumin 51 g/l. AFP was 4.2 µg/l. The CT scan showed that the tumor had become a 3 × 2 cm hypovascular lesion (Fig. 1h).

Fever following rigor was the most common adverse event and happened regularly after all the Ad-p53 injections. Rigor developed 2 h after injection and lasted 20–30 min. Then the body temperature started to increase and reached 39°C or higher. The highest reported temperature was 41°C. After treatment with cold foment or injection buplevurum (2 ml) intramuscularly, body temperature started to decrease 6 h after Ad-p53 injection and became normal 24 h after injection. Fatigue was another adverse event, and occurred three times after injection.

Discussion

HCC is a highly lethal cancer that typically has poor prognosis. To date, surgical approaches including liver resection and liver transplantation are regarded as potentially curative treatments for HCC, particularly in patients with small and noninvasive tumors [8]. However, in most patients the tumors are not suitable for surgical treatment because of multicentric tumors, extrahepatic metastases, early vascular invasion, shortage of donor organs, high complication rates, and comorbidities [8]. Combination of TACE and other methods of treatment might provide significant benefit in the treatment of HCC [9]. As the lesion occupied more than 50% of the liver volume, this patient was not suitable for surgery and therefore we tried this combination gene therapy. Multiple consecutive follow-up CT scans showed marked tumor shrinkage and the tumor had become a hypovascular lesion 828 days after starting treatment (Fig. 1h). In addition, the level of AFP decreased to 4.8 µg/l on post-TACE day 279 (65 days after finishing treatment), and remained normal up to the last follow-up visit on post-TACE day 828. Probably, this sustained effect was not because of the TACE and the chemotherapy.

The Ad-p53 injection used was gendicine, a recombinant human serotype 5 adenovirus in which the E1 region is replaced by a human wild-type p53 expression cassette. Gendicine obtained a drug license from the State Food

and Drug Administration of China (Beijing, China) and became the world's first commercially licensed gene therapy drug. Gendicine was stored at -20°C at a concentration of 1×10^{12} VPs/ampoule, and was thawed out and diluted in 5 ml physiological saline solution for injection at room temperature within 30 min before administration.

Deletions or mutations of wild-type p53 have been identified in approximately 50% of all tumor types. In HCC, the incidence of p53 mutation was reported to be 61% and its presence in HCC indicates a poorer prognosis [10,11]. Inactivity of p53 may abrogate an effective apoptotic response to chemotherapy. It is reported that exogenous p53 renders HCC more sensitive to some chemotherapeutic agents [12]. Moreover, wild-type p53 gene transfection increased the sensitivity of acquired 5-FU-resistant HCC cells to 5-FU [13].

Transduction of the wild-type p53 gene in the tumor is a promising gene therapy strategy in the treatment of cancer. Selective and less invasive gene delivery to the liver tumor is, however, necessary for clinical HCC gene therapy. The main approaches for HCC gene therapy are intratumor injection. Multicentric occurrence and intrahepatic micrometastases frequently occur in patients with HCC. Intratumoral vector injection can only be applied to a limited number of visible lesions per patient. Even for single HCC, intratumoral vector injection cannot cover the lesion when its diameter is greater than 3 cm. Effective organ-targeting approaches for HCC gene therapy are immediately required. About 90% of the blood supply to liver cancer comes through the hepatic artery [14]. Implanted PCS allows easy, repeated-introduction of target genes and drugs into the hepatic artery, causing less vessel damage and discomfort. Moreover, this approach allows ambulatory treatment and avoids repetitive arterial access. We injected eight times through PCS for this patient without complication.

Fever was the most common adverse event of the Ad-p53 injections [15–17]. Transient fever has been previously reported as an adverse event after intravenous administration of Ad-p53 in patients with advanced cancer [18]. The vector of Ad-p53 is replication-deficient adenovirus. Regular fever following rigor after injection could be because of the transient systemic spread of the vector. The fever was self-limiting and did not need antiviral treatment. Body temperature became normal when the vectors had been cleared. There was no progression of toxicity grade despite repeated (10 times) injections of Ad-p53 in this patient.

This case suggests that the combination of p53 gene therapy, TACE, and chemotherapy may be useful in the treatment of patients with unresectable HCC in the

future, although controlled clinical trials are needed to assess the efficacy of this treatment.

References

- 1 Parkin DM, Bray F, Ferlay J, Pisani P. Estimating the world cancer burden: Globocan 2000. *Int J Cancer* 2001; **94**:153–156.
- 2 Biselli M, Andreone P, Gramenzi A, Trevisani F, Cursaro C, Rossi C, *et al.* Transcatheter arterial chemoembolization therapy for patients with hepatocellular carcinoma: a case controlled study. *Clin Gastroenterol Hepatol* 2005; **3**:918–925.
- 3 Levine AJ. p53, the cellular gatekeeper for growth and division. *Cell* 1997; **88**:323–331.
- 4 Boige V, Raoul JL, Pignon JP, Bouché O, Blanc JF, Dahan L, *et al.* Multicentre phase II trial of capecitabine plus Oxaliplatin (XELOX) in patients with advanced hepatocellular carcinoma: FFCD 03-03 trial. *Br J Cancer* 2007; **97**:862–867.
- 5 Qin SK, Cao MR, Qian J, Hua HQ, Wang L, He ZM. Clinical study of FOLFOX regimen for the patients with advanced hepatocellular carcinoma. *Chin Clin Oncol* 2005; **10**:58–60.
- 6 Peng ZH. Current status of Gendicine in China: recombinant human Ad-p53 agent for treatment of cancers. *Hum Gene Ther* 2005; **16**:1016–1027.
- 7 Guan YS, Sun L, Zhou XP, Li X, He Q, Liu Y. Combination therapy with recombinant adenovirus-p53 injection (rAd-p53) via transcatheter hepatic arterial chemoembolization for advanced hepatic carcinoma. *Shijie Huaren Xiaohua Zazhi* 2005; **13**:125–127.
- 8 Williams R, White J, Croce M, Dilawari R. Surgical options in the treatment of hepatocellular carcinoma. *Am Surg* 2007; **73**:58–62.
- 9 Alsowmely AM, Hodgson HJ. Non-surgical treatment of hepatocellular carcinoma. *Aliment Pharmacol Ther* 2002; **16**:1–15.
- 10 Hsia CC, Nakashima Y, Thorgeirsson SS, Harris CC, Minemura M, Momosaki S, *et al.* Correlation of immunohistochemical staining and mutations of p53 in human hepatocellular carcinoma. *Oncol Rep* 2000; **7**:353–356.
- 11 Honda K, Sbisà E, Tullo A, Papeo PA, Saccone C, Poole S, *et al.* p53 mutation is a poor prognostic indicator for survival in patients with hepatocellular carcinoma undergoing surgical tumour ablation. *Br J Cancer* 1998; **77**:776–782.
- 12 Takeba Y, Sekine S, Kumai T, Matsumoto N, Nakaya S, Tsuzuki Y, *et al.* Irinotecan-induced apoptosis is inhibited by increased P-glycoprotein expression and decreased p53 in human hepatocellular carcinoma cells. *Biol Pharm Bull* 2007; **30**:1400–1406.
- 13 Li YX, Lin ZB, Tan HR. Wild type p53 increased chemosensitivity of drug-resistant human hepatocellular carcinoma Bel7402/5-FU cells. *Acta Pharmacol Sin* 2004; **25**:76–82.
- 14 Lu CD. Blood supply of hepatic neoplasm. *Foreign Med Sci Oncol Sect* 1991; **18**:19–22.
- 15 Fujiwara T, Tanaka N, Kanazawa S, Ohtani S, Saijo Y, Nukiwa T, *et al.* Multicenter phase I study of repeated intratumoral delivery of adenoviral p53 in patients with advanced non-small-cell lung cancer. *J Clin Oncol* 2006; **24**:1689–1699.
- 16 Buller RE, Runnebaum IB, Karlan BY, Horowitz JA, Shahin M, Buekers T, *et al.* A phase I/II trial of rAd/p53 (SCH 58500) gene replacement in recurrent ovarian cancer. *Cancer Gene Ther* 2002; **9**:553–566.
- 17 Clayman GL, Frank DK, Bruso PA, Goepfert H. Adenovirus-mediated wild-type p53 gene transfer as a surgical adjuvant in advanced head and neck cancers. *Clin Cancer Res* 1999; **5**:1715–1722.
- 18 Tolcher AW, Hao D, de Bono J, Miller A, Patnaik A, Hammond LA, *et al.* Phase I, pharmacokinetic, and pharmacodynamic study of intravenously administered Ad-CMV-p53, an adenoviral vector containing the wild-type p53 gene, in patients with advanced cancer. *J Clin Oncol* 2006; **24**:2052–2058.